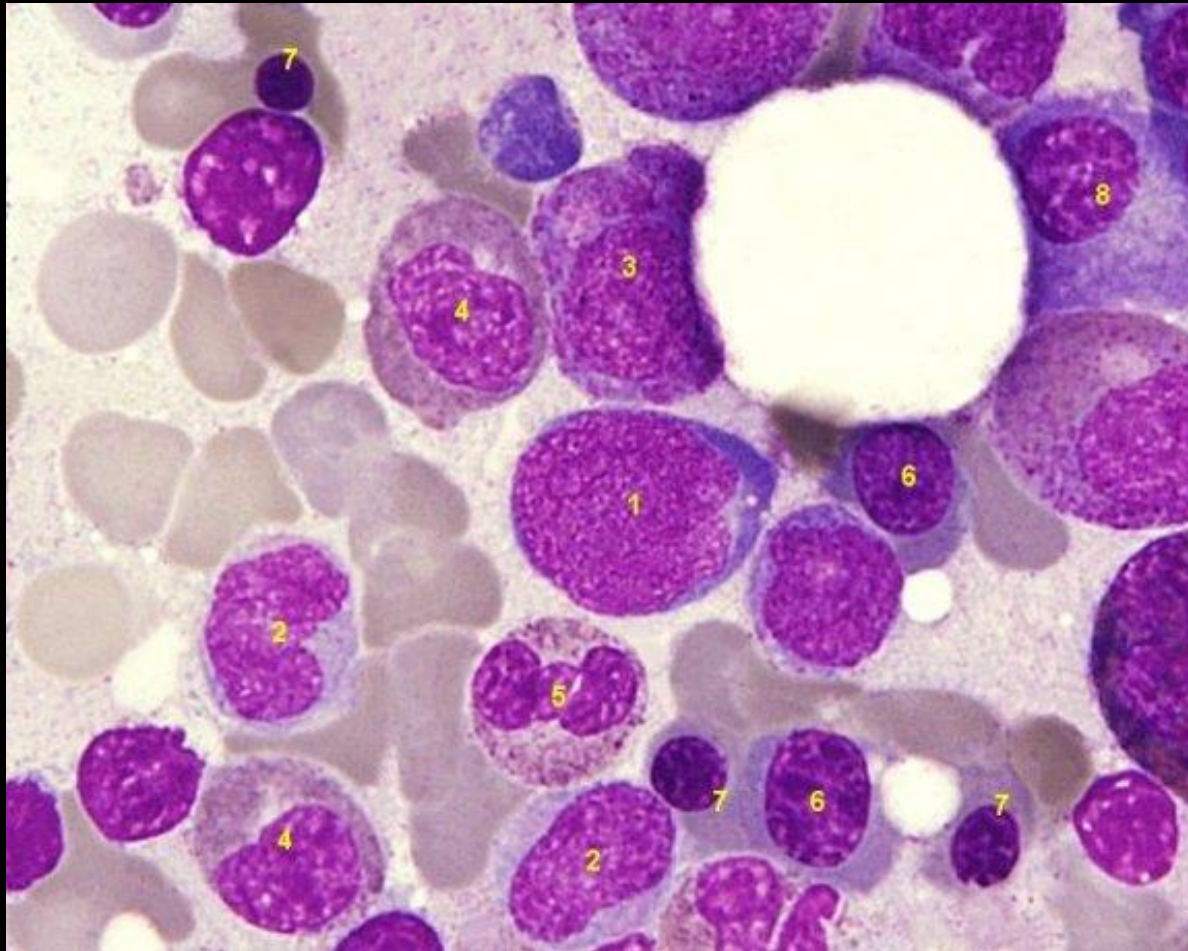


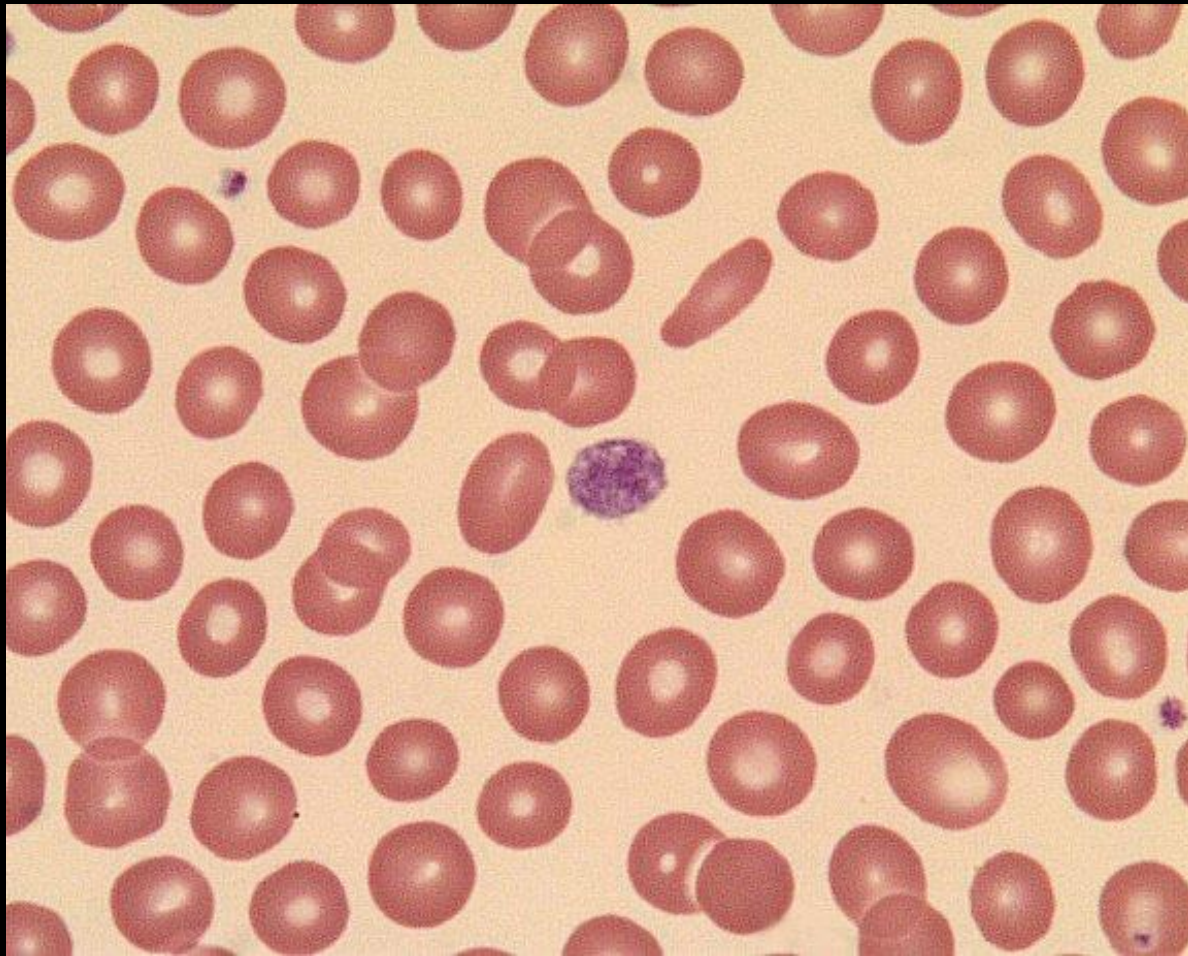
A tropical sunset scene with palm trees and a large sun over the ocean. The sky is filled with soft, orange and yellow clouds. The sun is a large, bright orange circle on the horizon, reflecting on the water. Several palm trees are silhouetted against the sky, with one particularly tall tree in the foreground on the left. The overall mood is peaceful and serene.

PLATELET

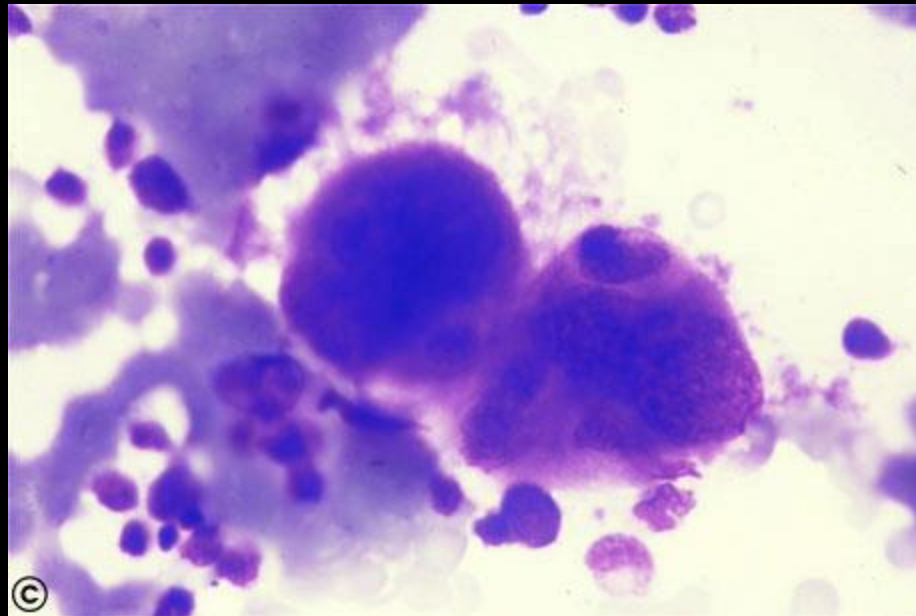
1. megakaryoblast
2. monocyte
3. promyelocyte
4. neutrophilic myelocyte
5. segmented neutrophil
6. intermediate erythroblast



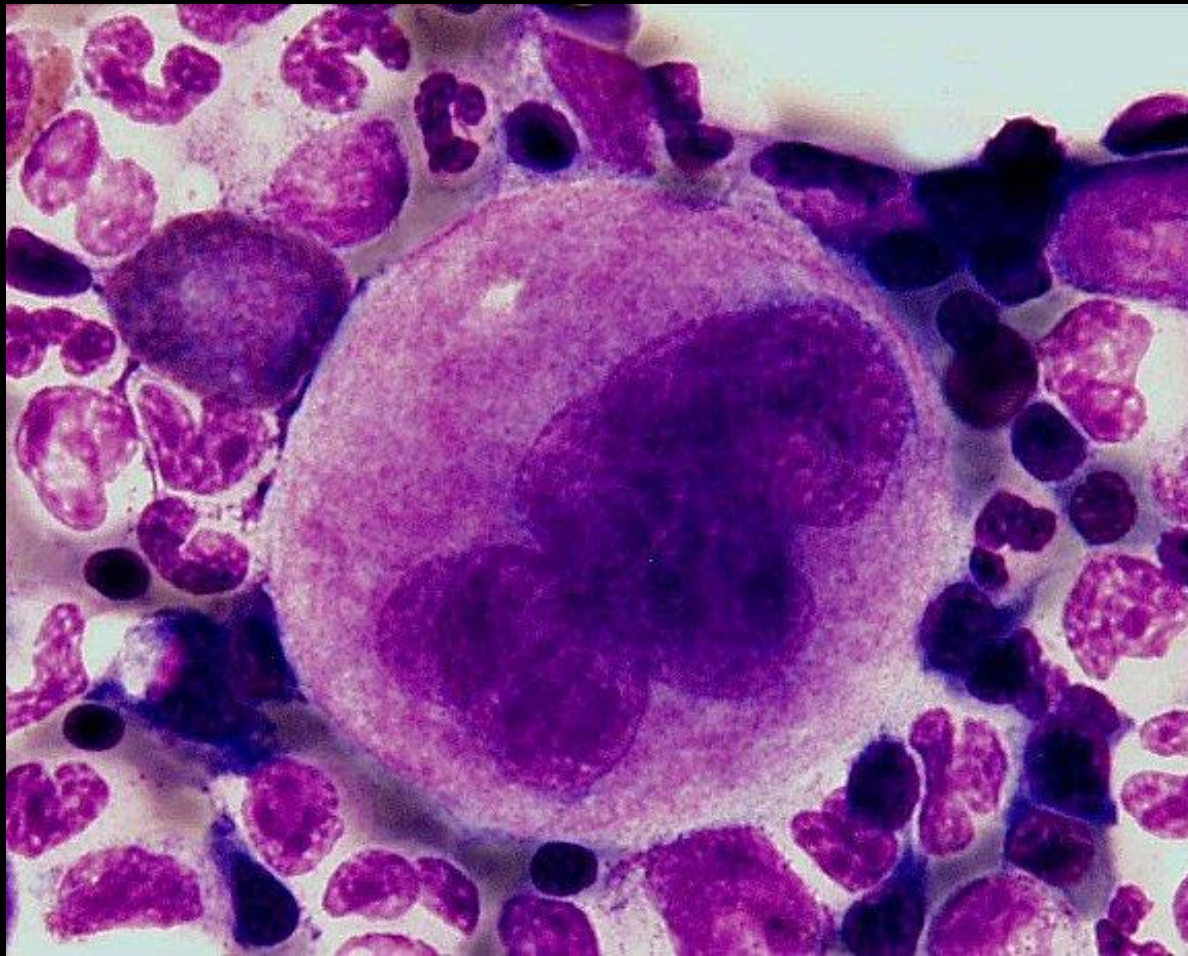
GIANT PLATELETS



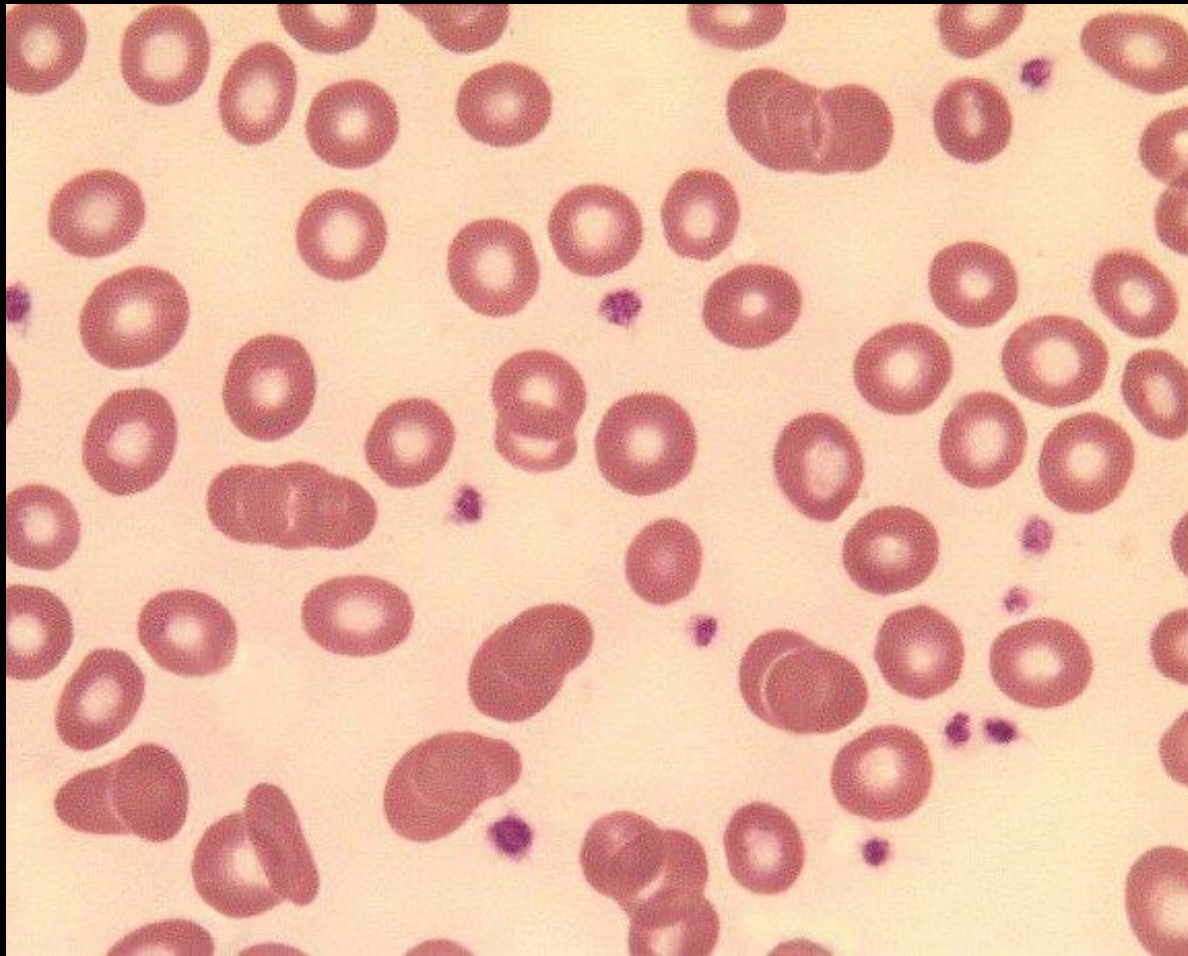
megakariocyte



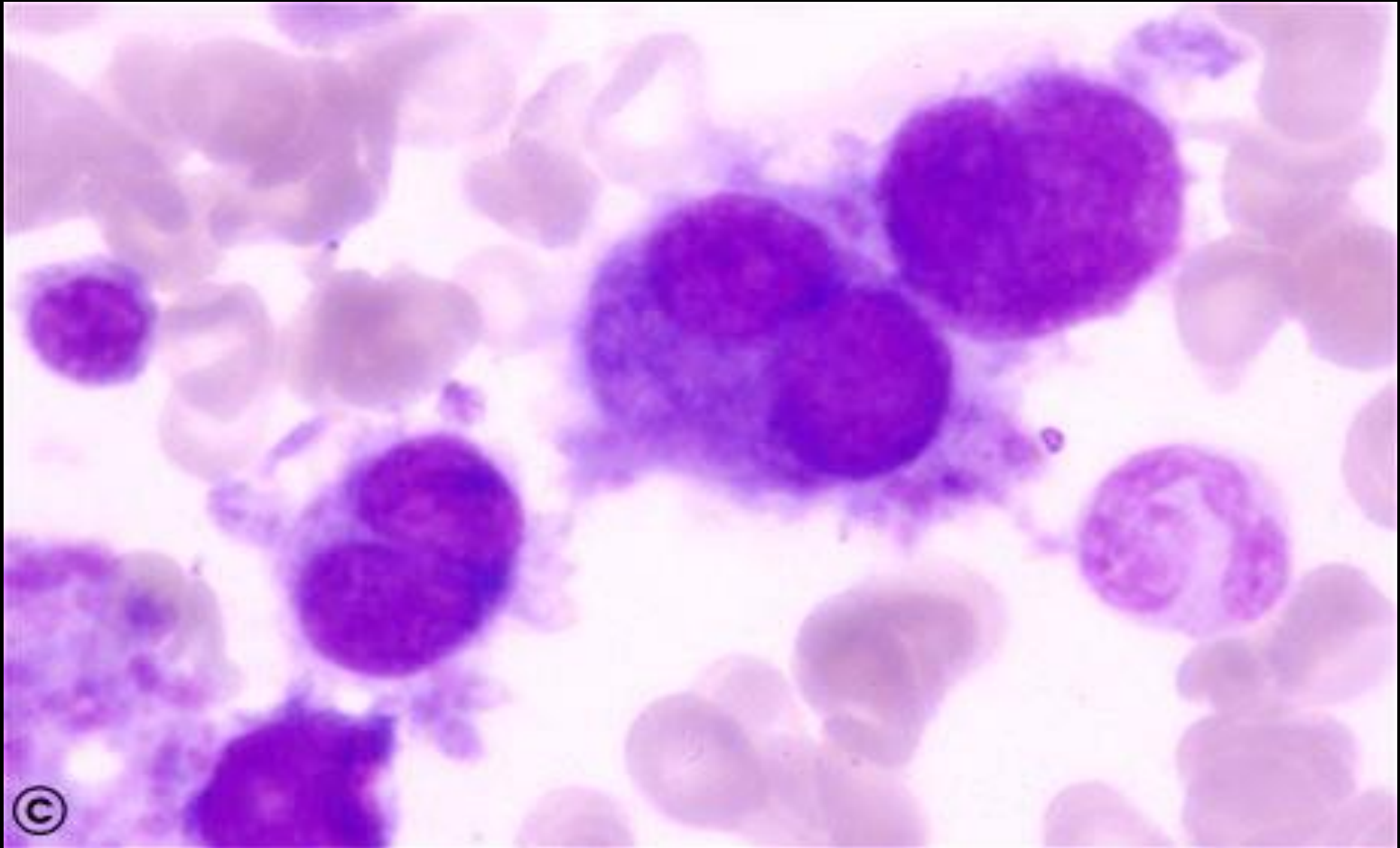
MEGAKARYOCYTES



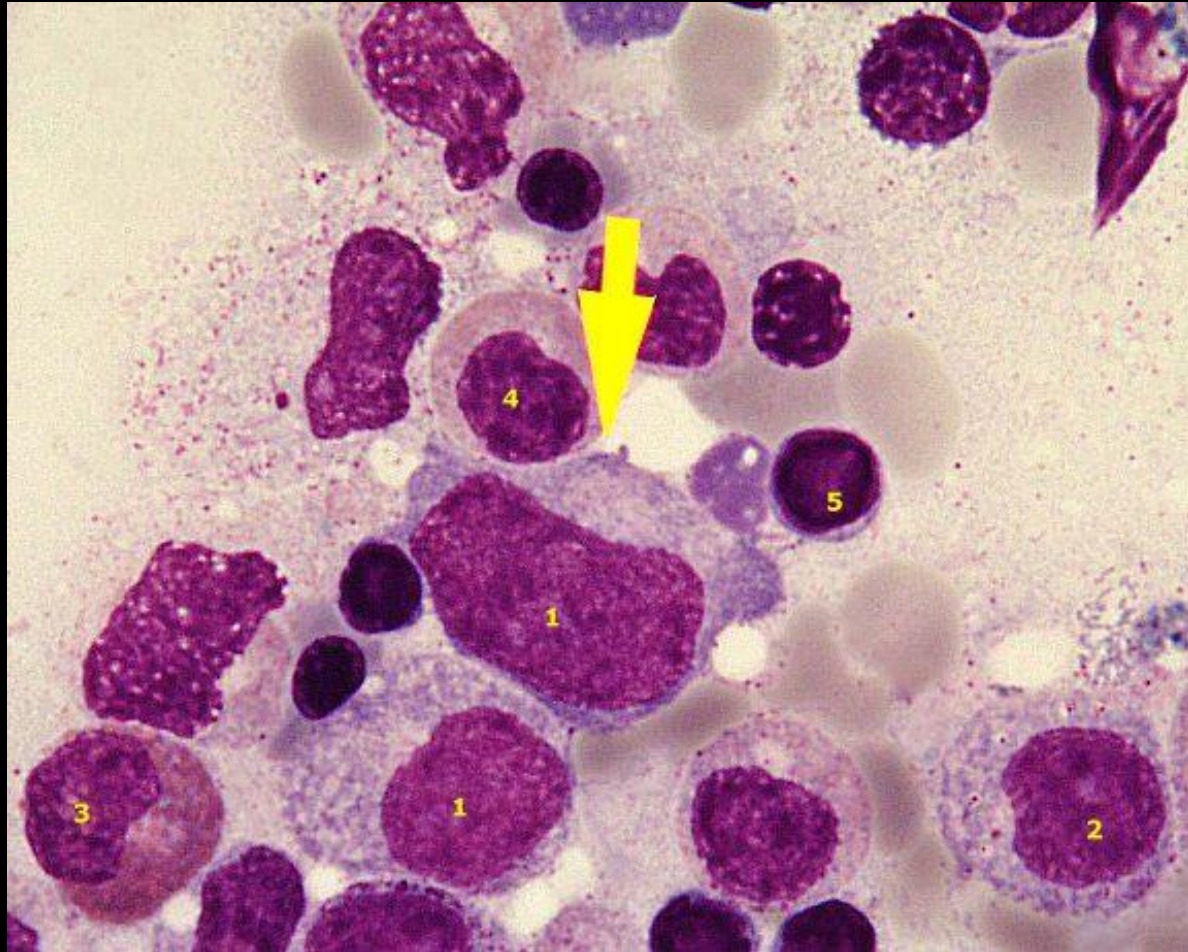
Normal platelets .



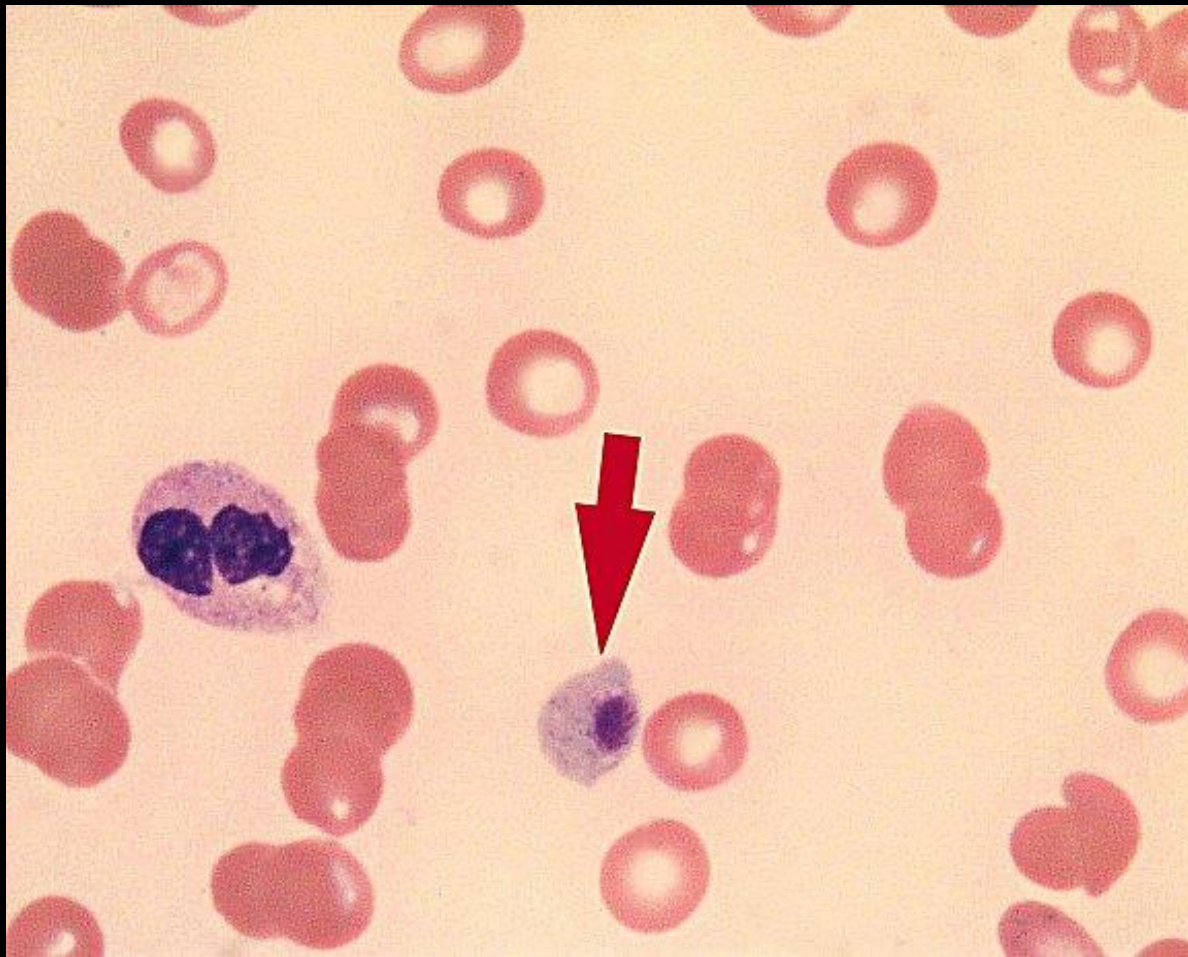
promegakaryocyte



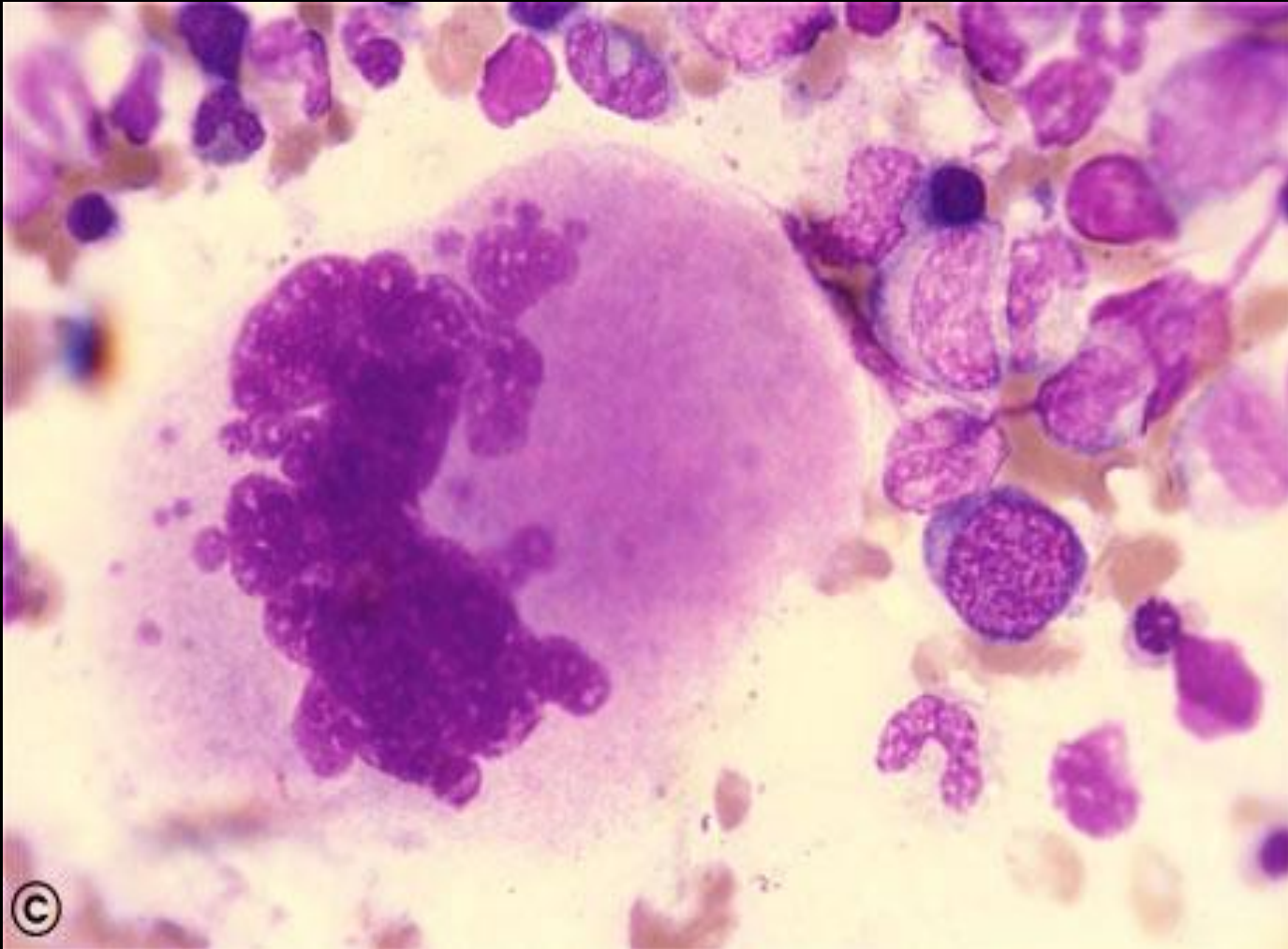
1. megakaryoblast
2. promyelocyte
3. eosinophil
4. metamyelocyte
5. neutrophil



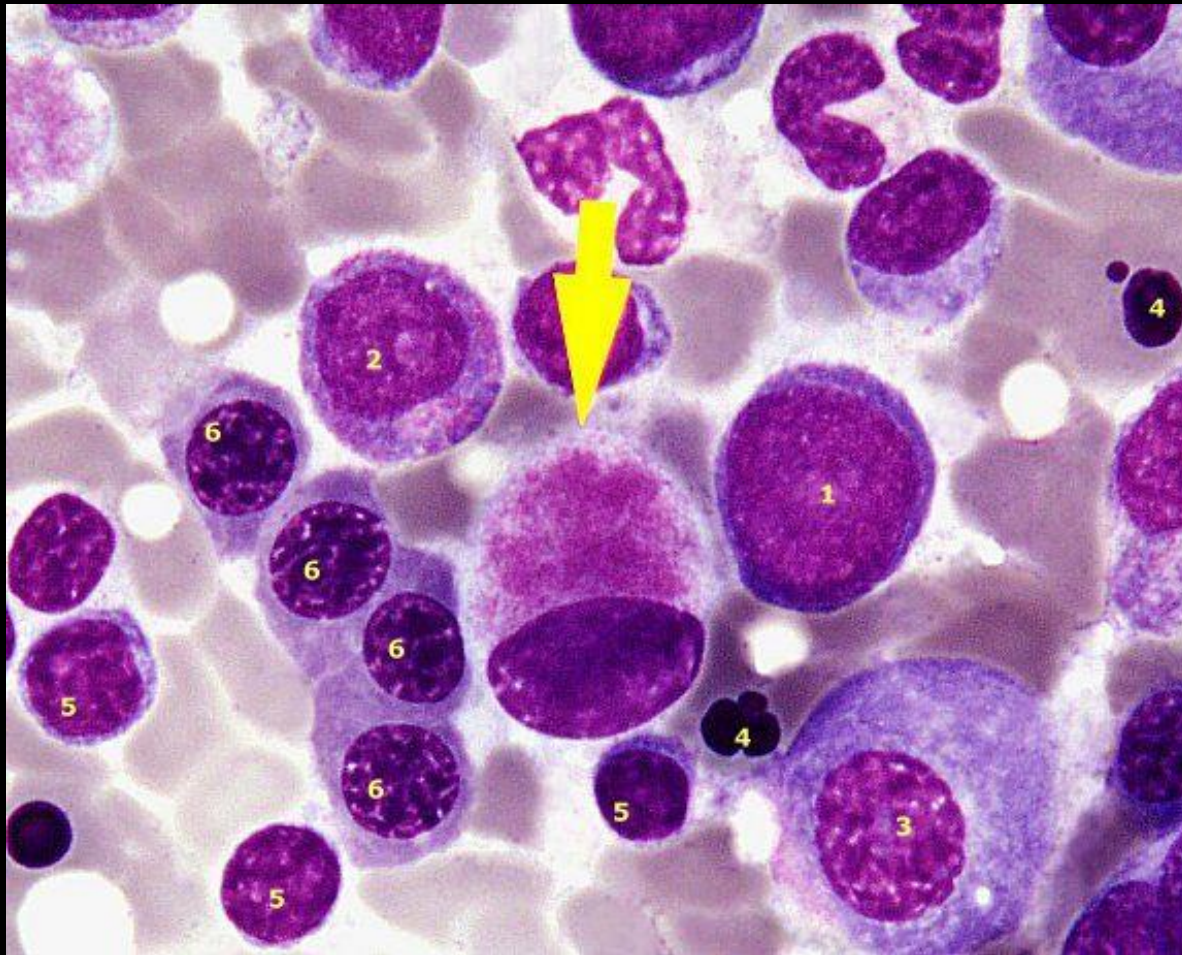
Hypogranular platelets



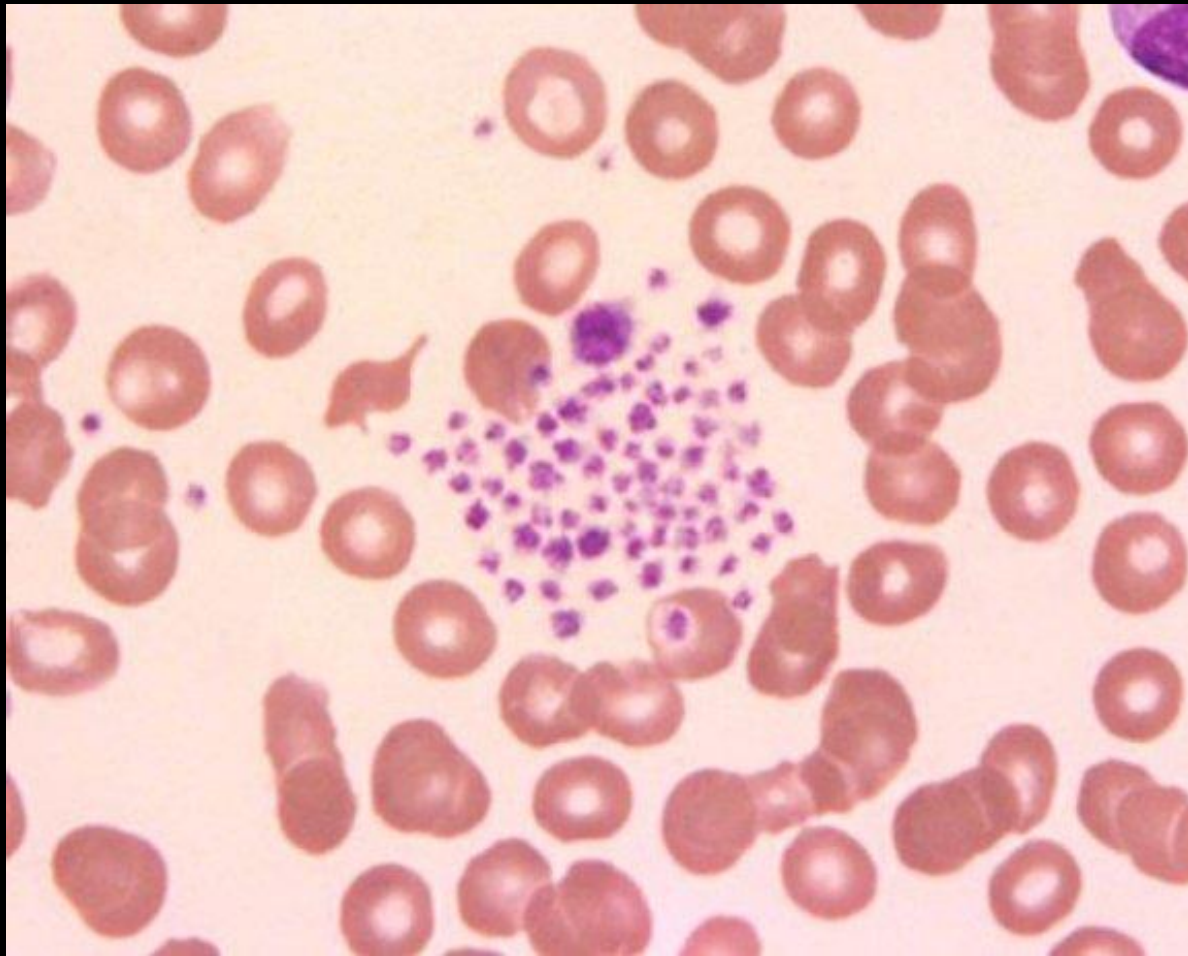
megakariocyte



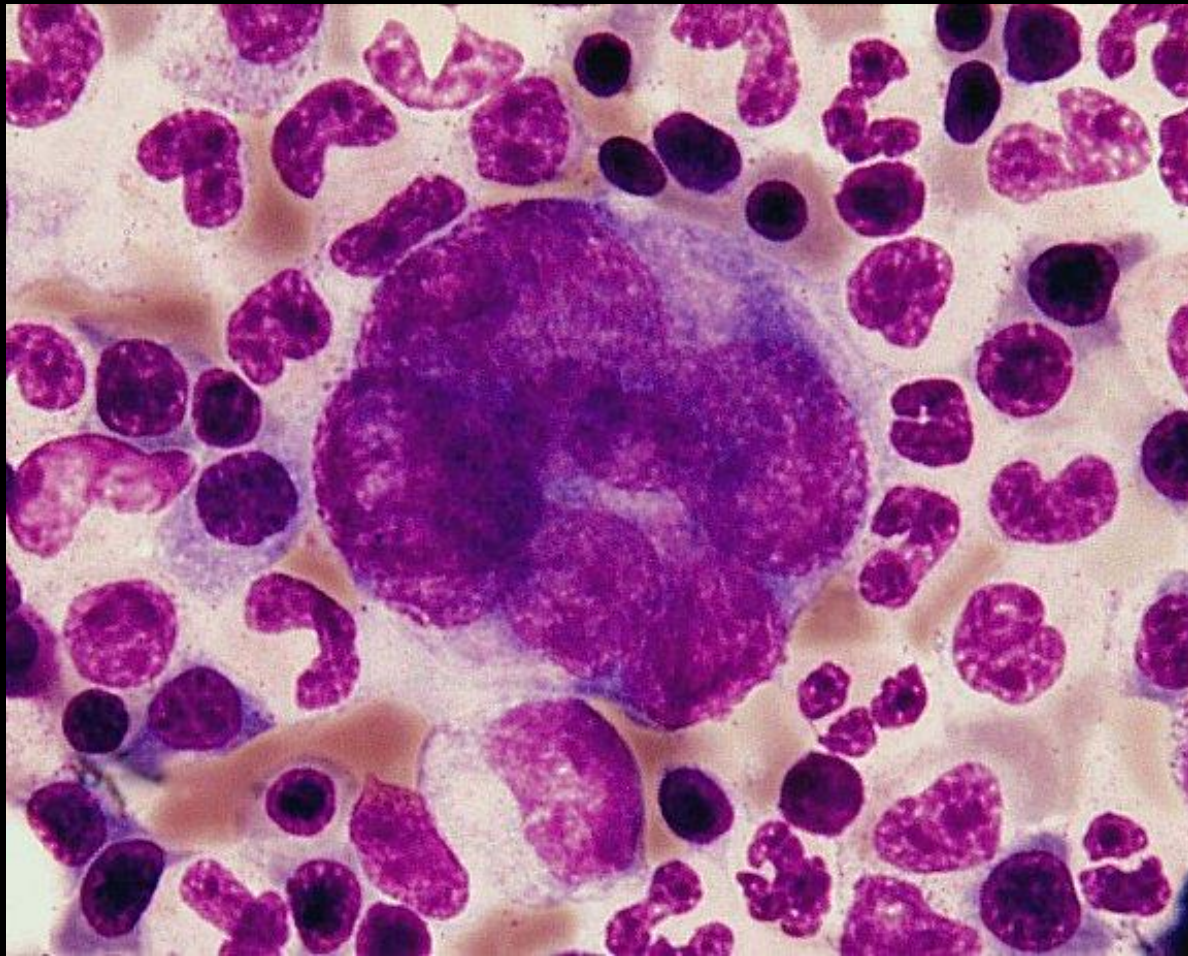
MICROMEGLAKARYOCYTES 1. myeloblast 2.
promyelocyte 3. plasmocyte 4. paraerythroblast
5. lymphocyte 6. polychromatic normoblast



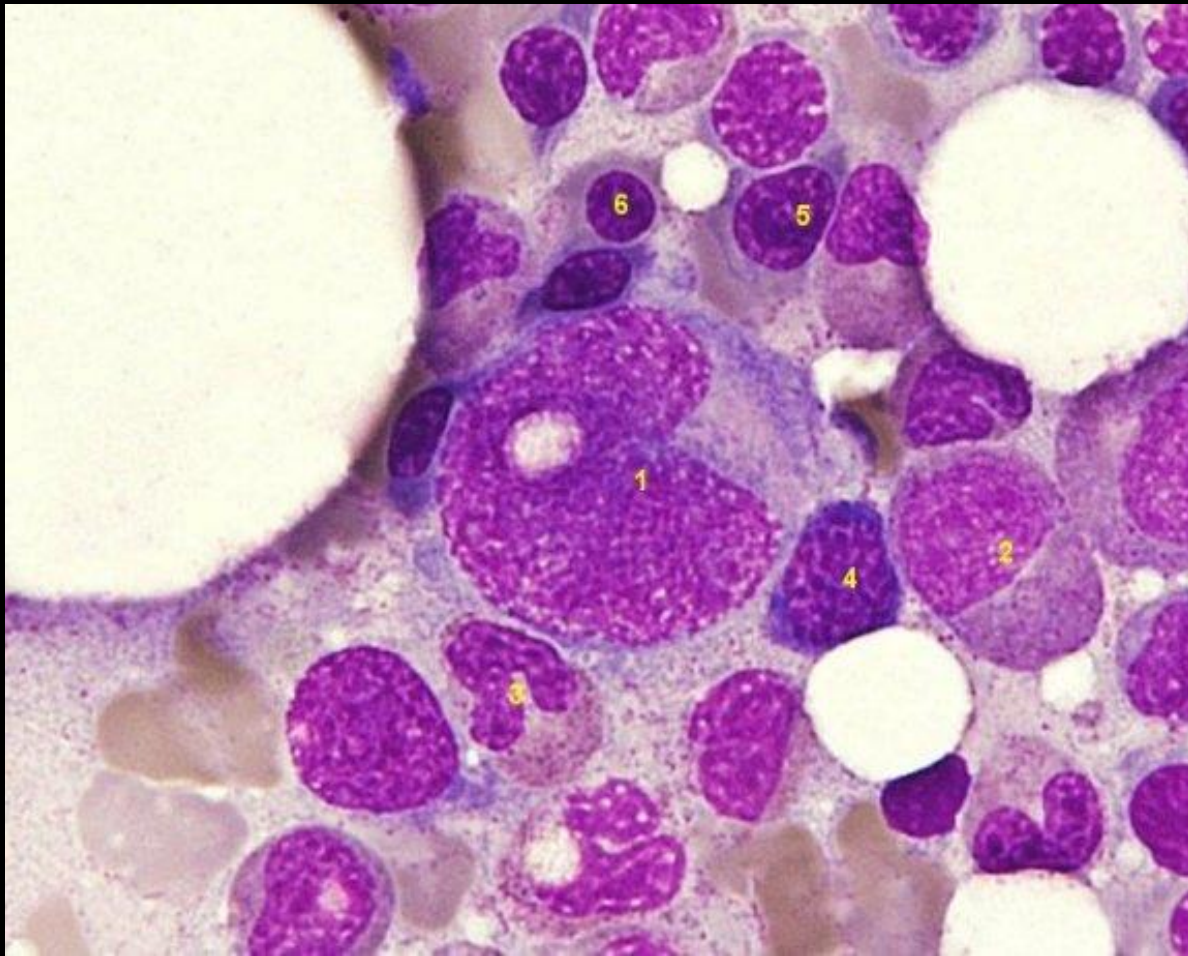
PLATELETS AGGREGATES



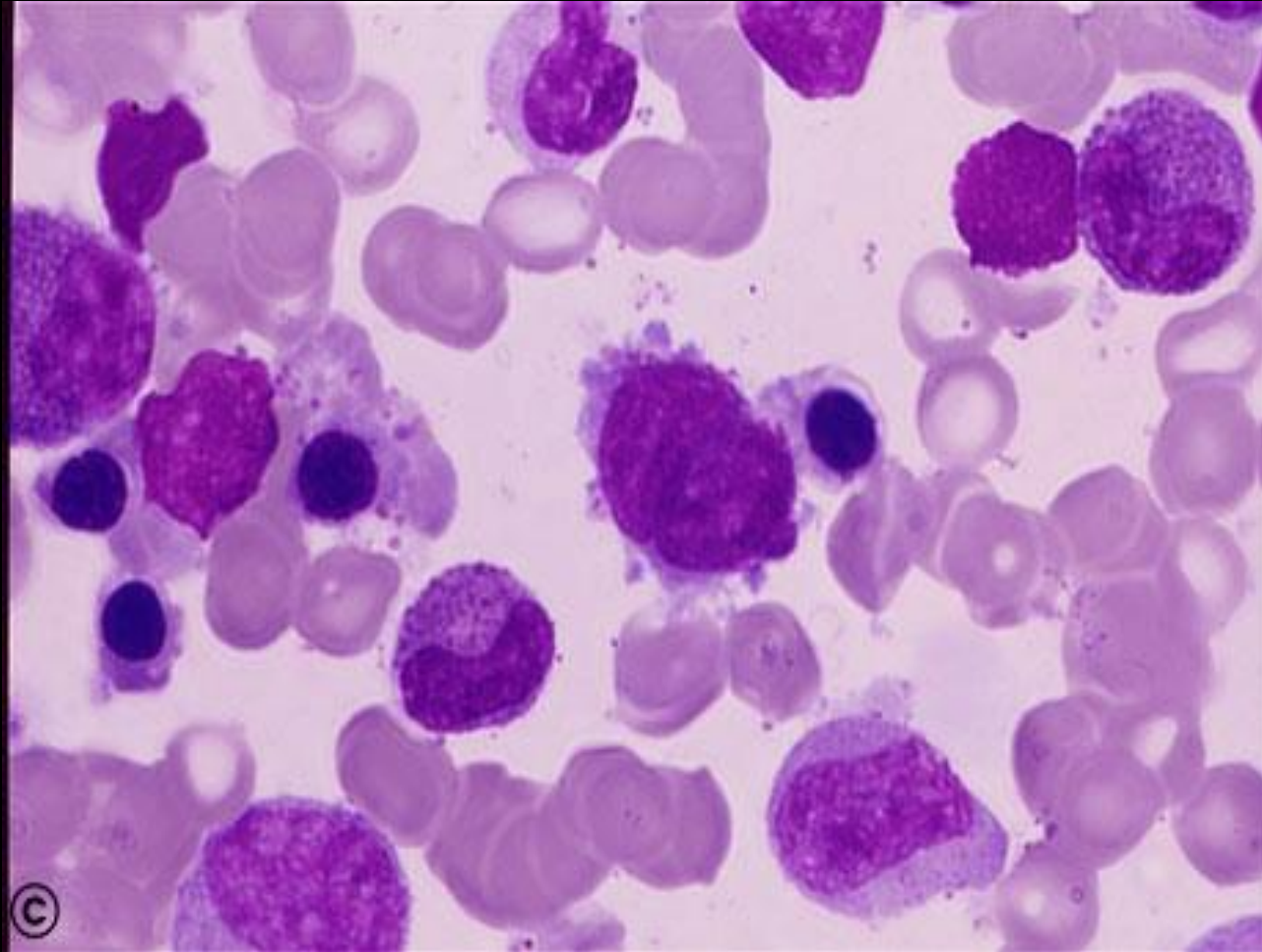
PROMEGAKARYOCYTES



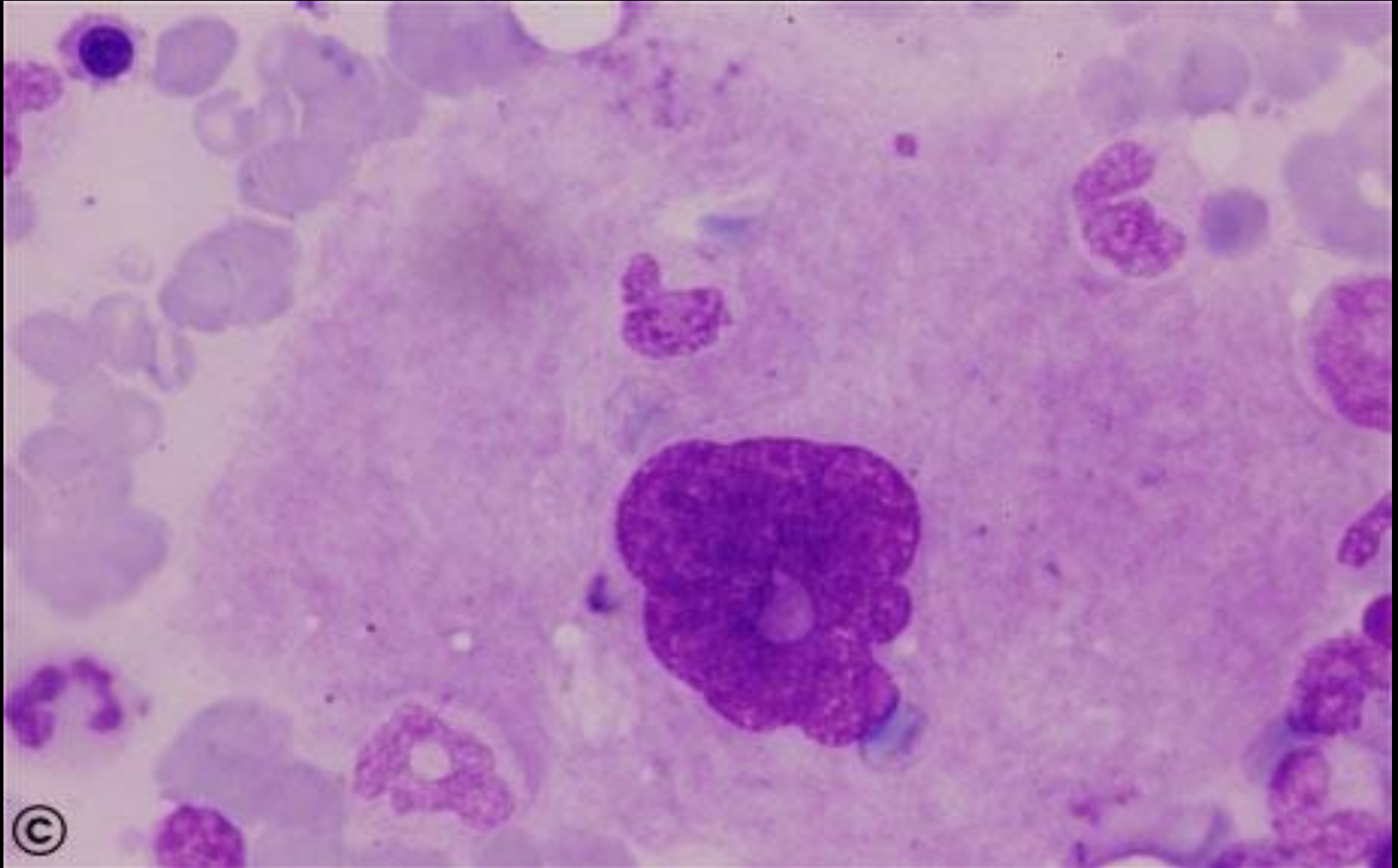
1. promegakaryocyte
2. neutrophilic myelocyte
3. band neutrophil
4. basophilic erythroblast
5. intermediate erythroblast
6. intermediate erythroblast



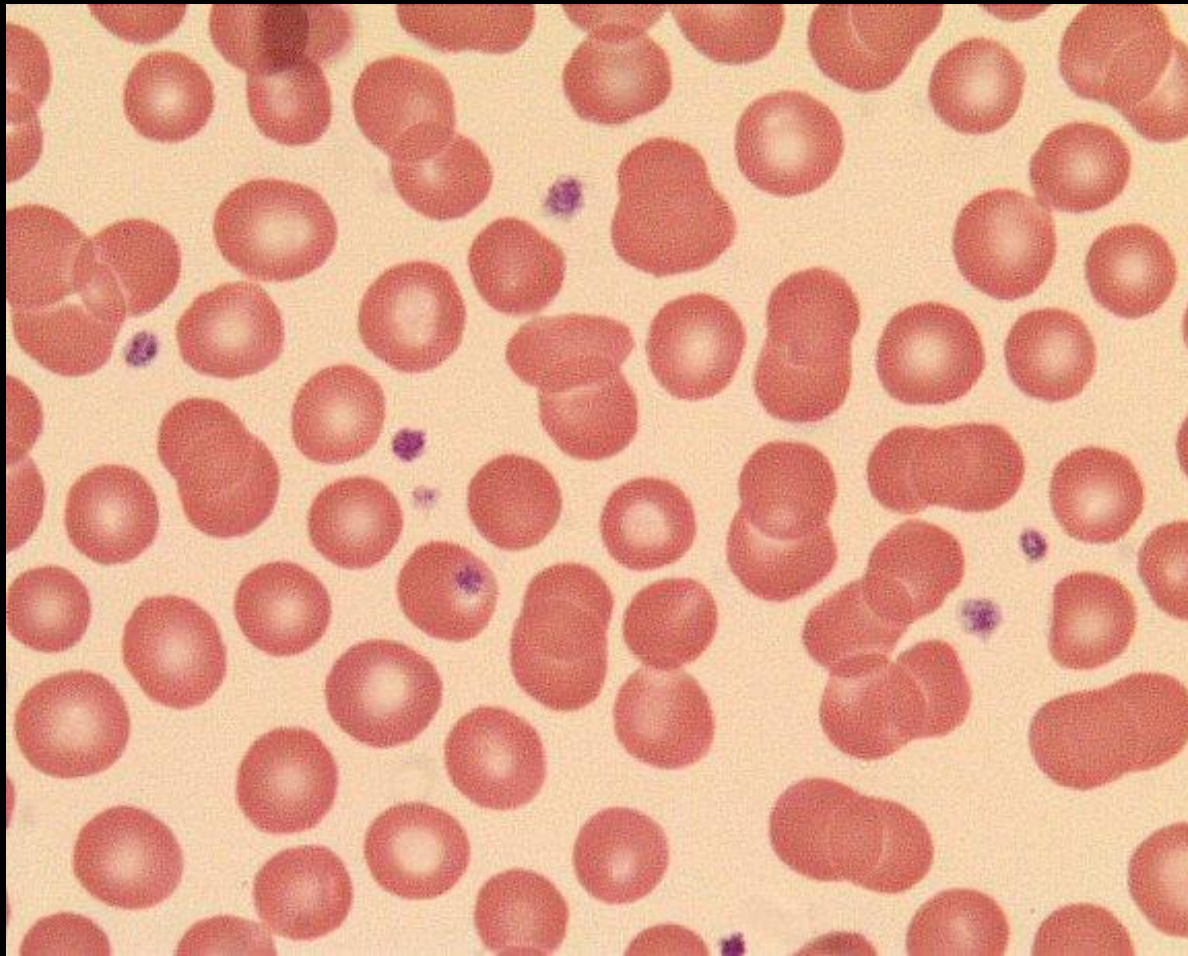
megakarioblast



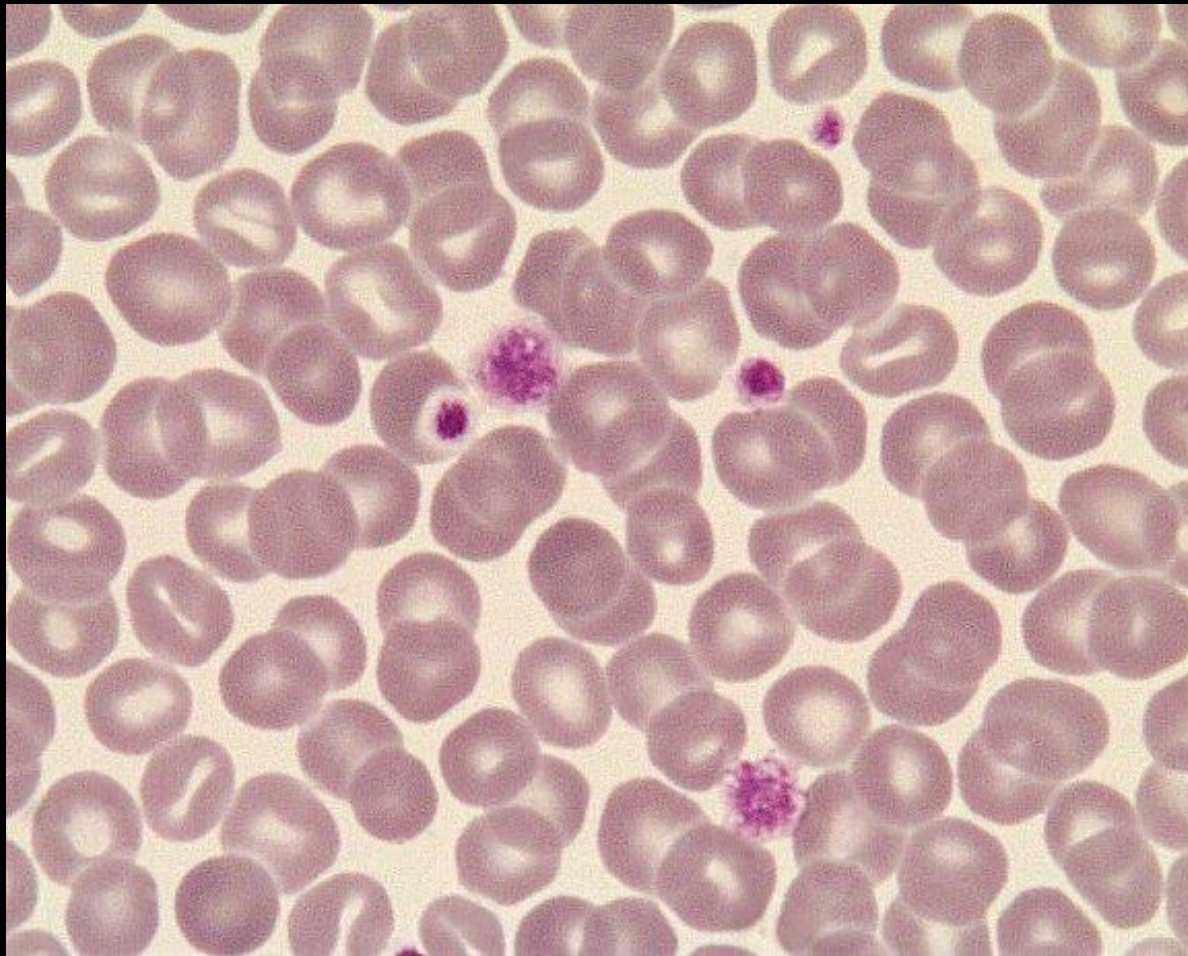megakariocyte



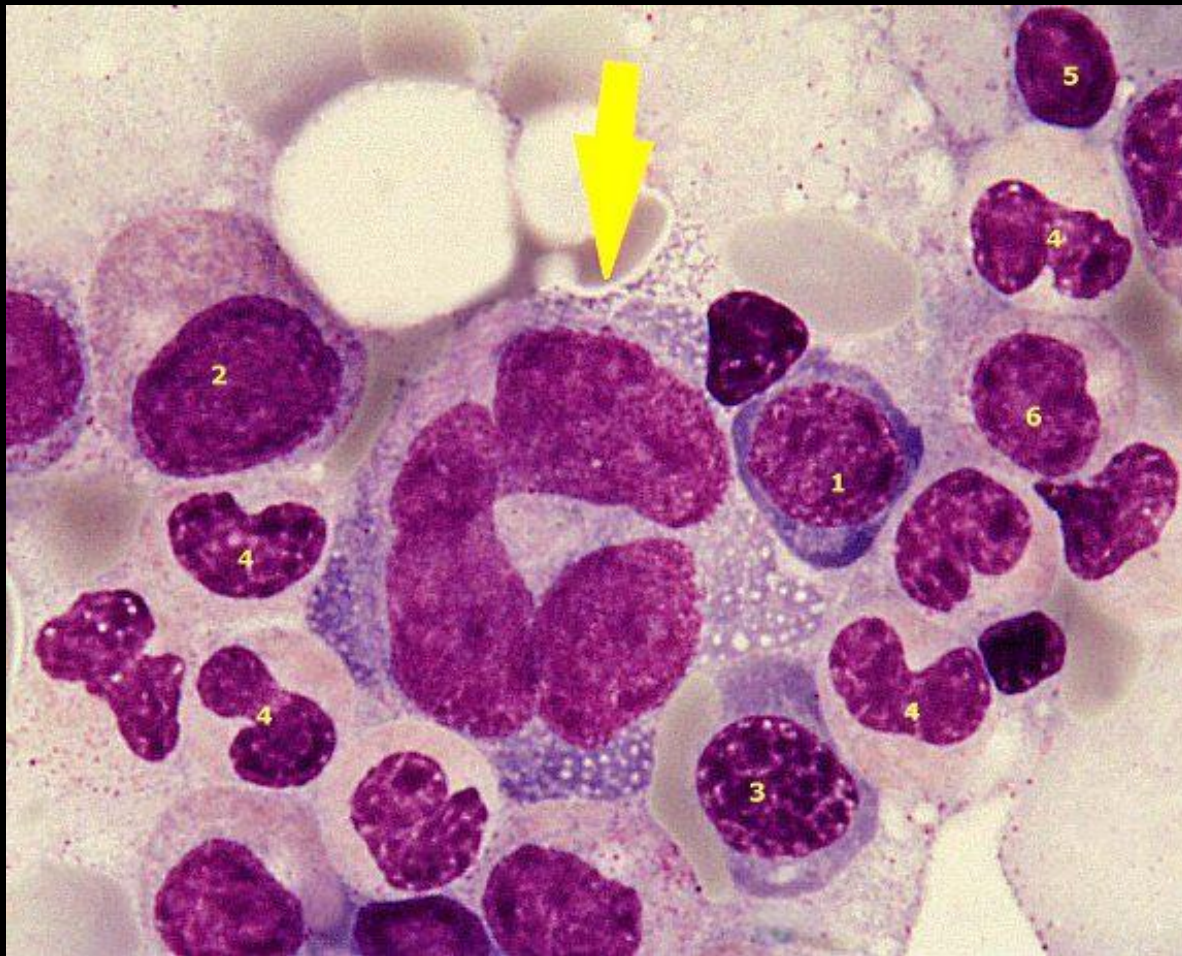Normal platelets



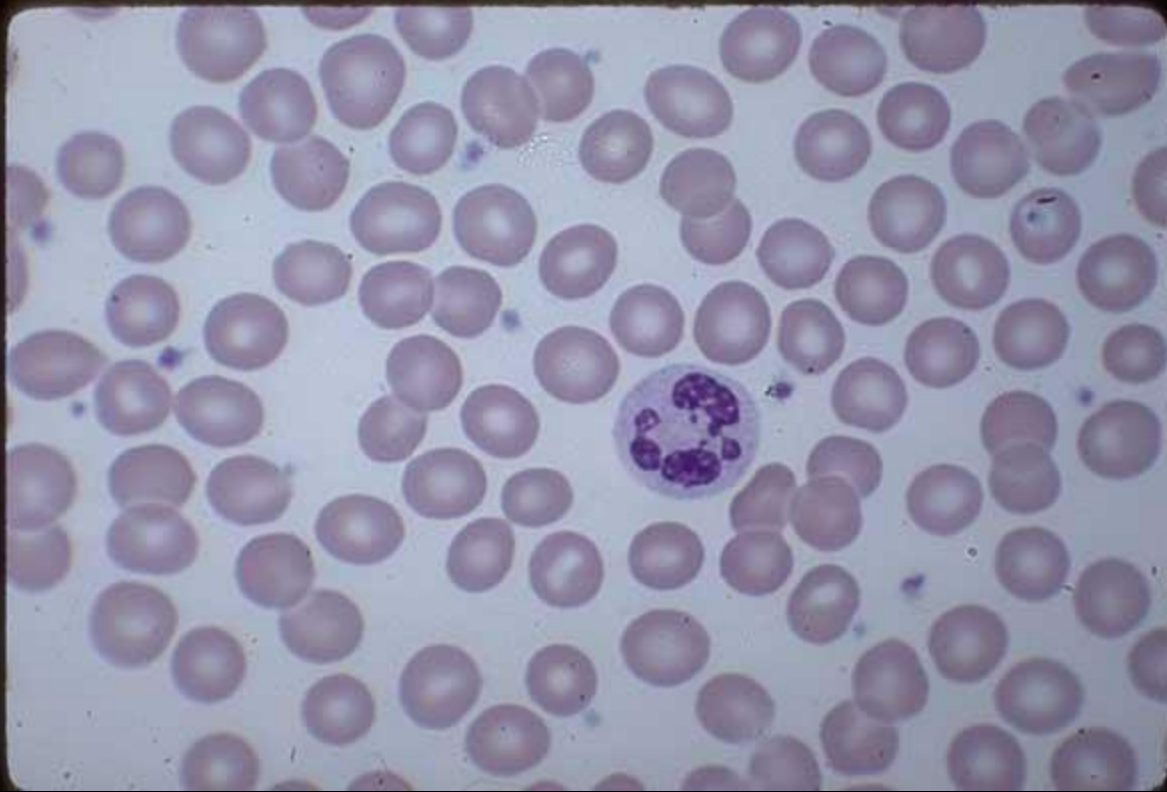PLATELETS ANISOCYTOSIS



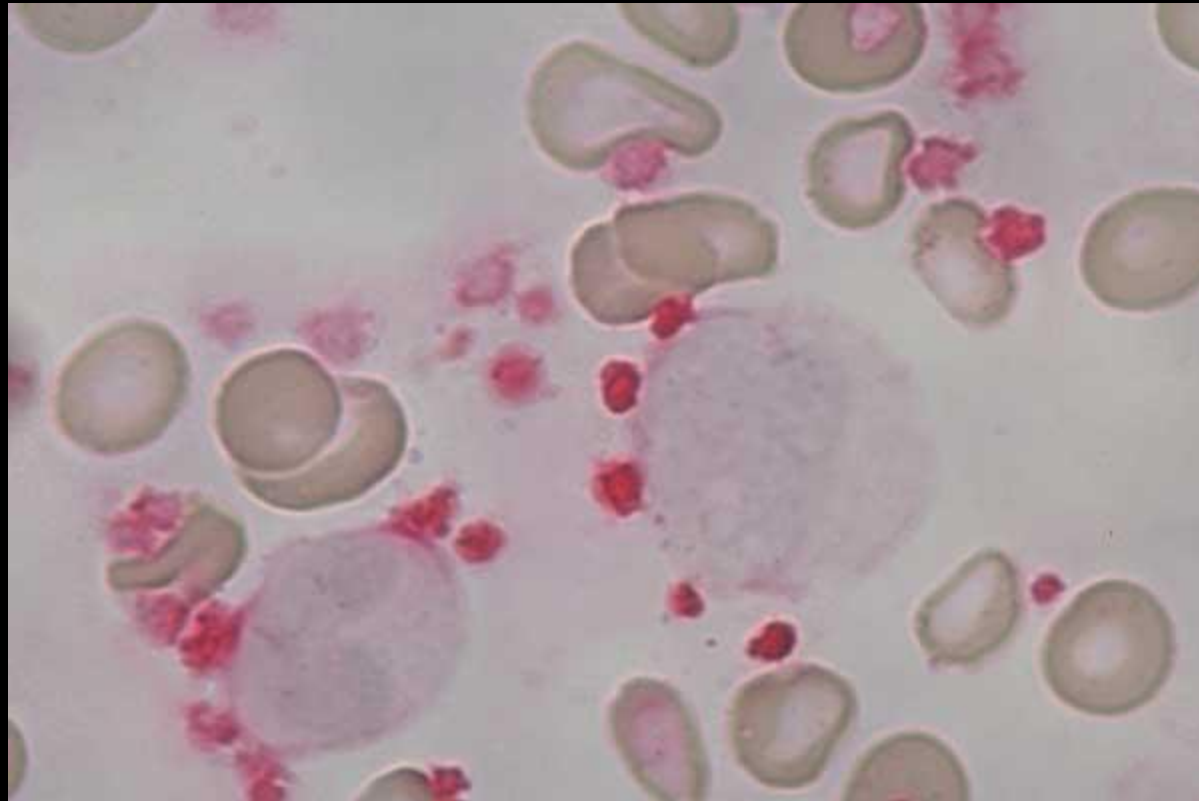
PROMEGAKARYOCYTES .1. proerythroblast 2. promyelocyte 3. polychromatic normoblast 4. neutrophil metamyelocyte 5. lymphocyte 6. neutrophil myelocyte



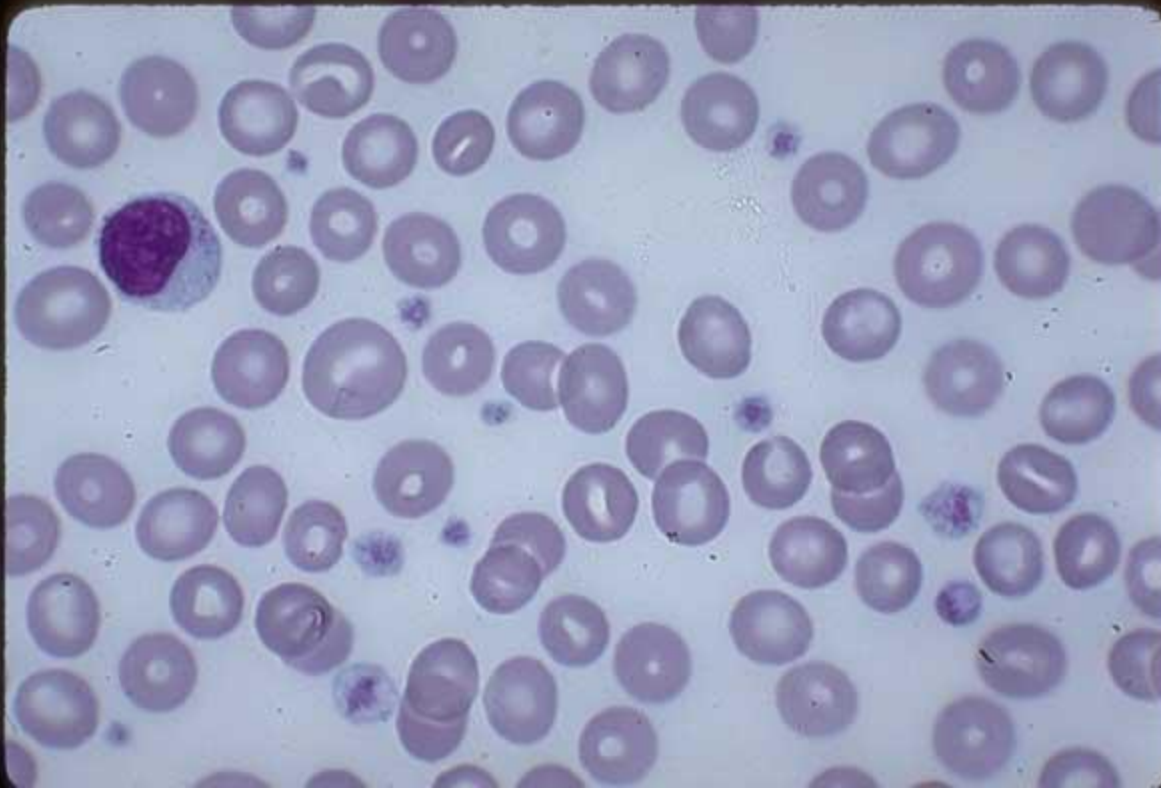
Normal Platelets, Normal EDTA anticoagulated blood



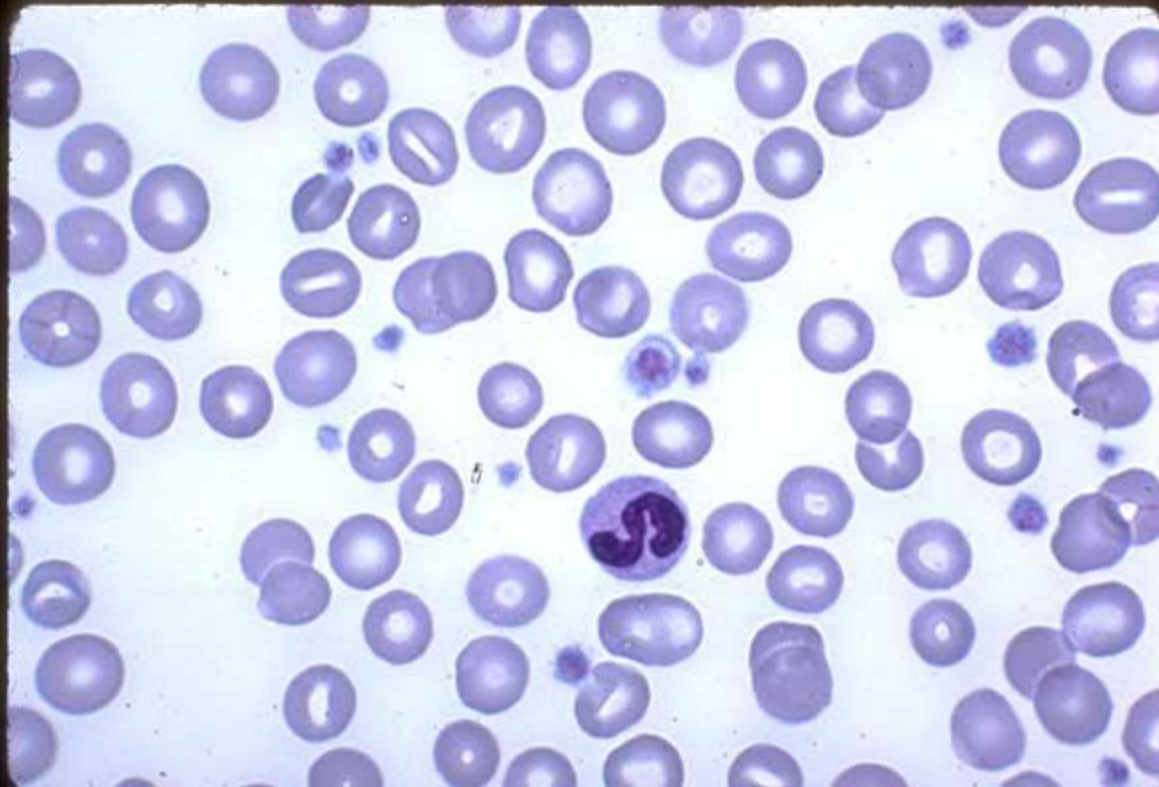
Platelets, neutrophil, monocyte, GP IIb/IIIa stain



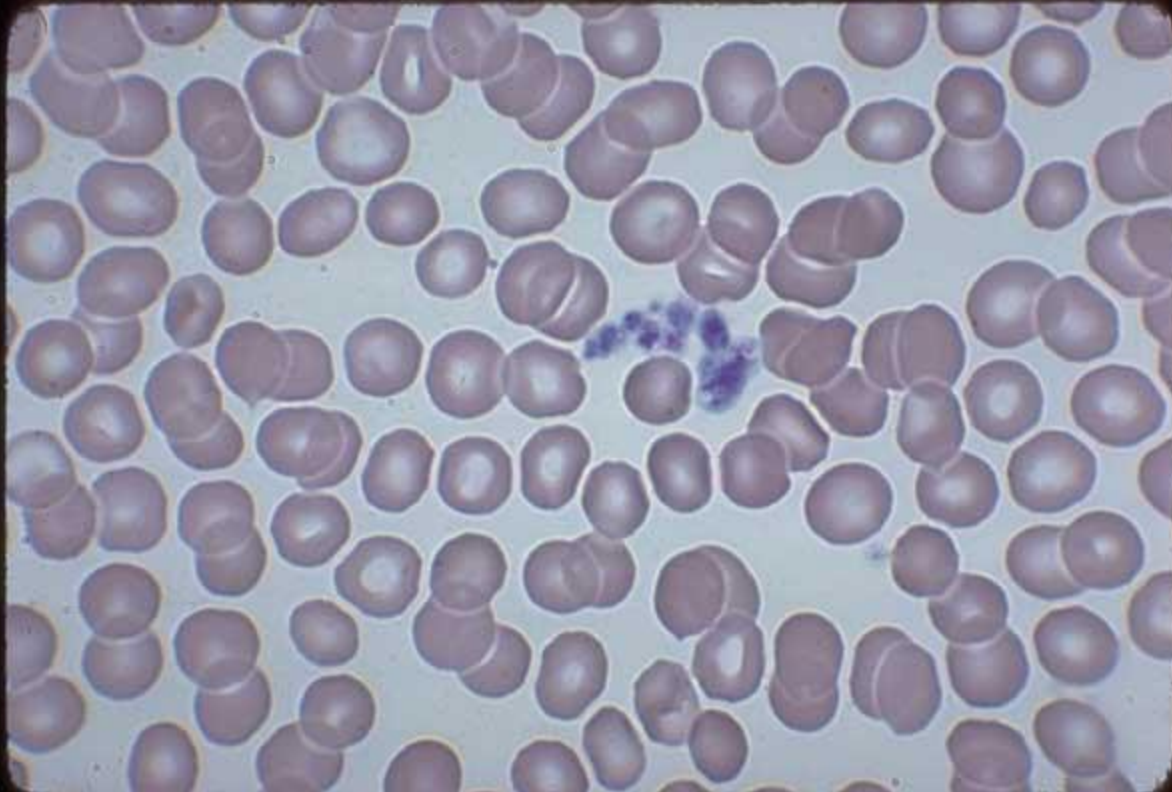Platelets, Normal EDTA anticoagulated blood



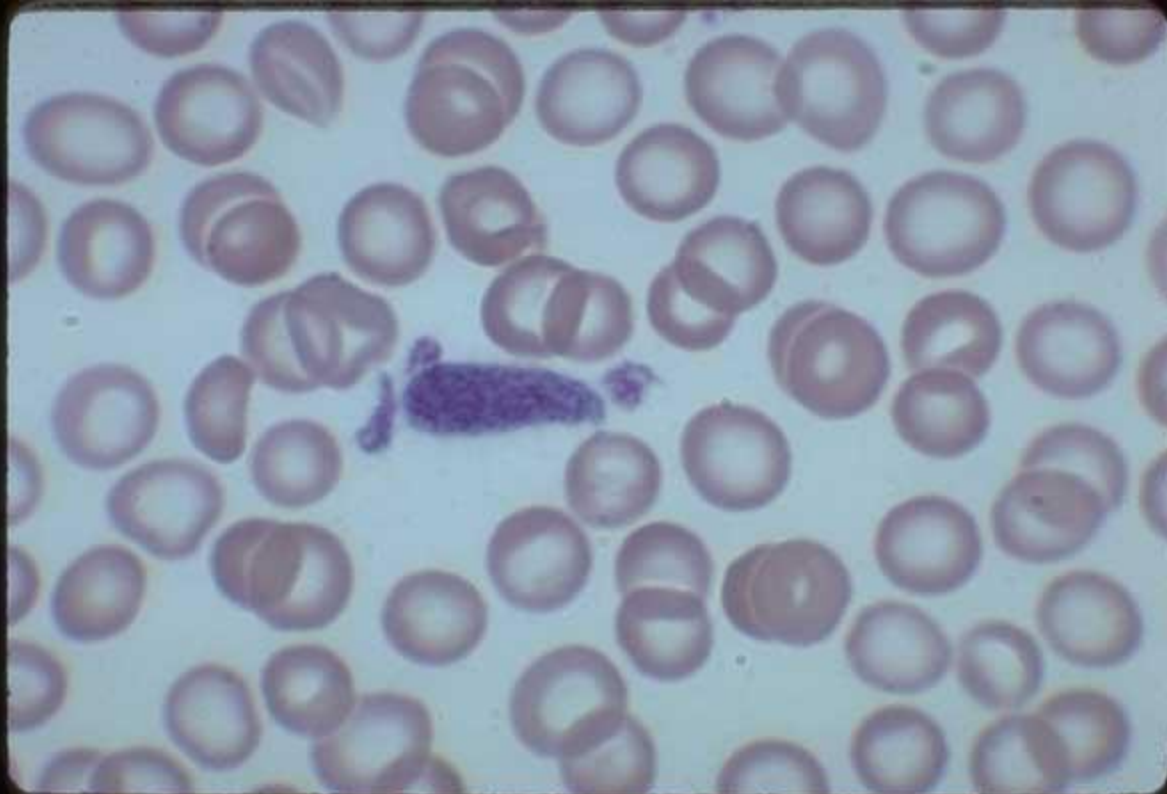
Small Platelets, Megathrombocyte, Band Neutrophil



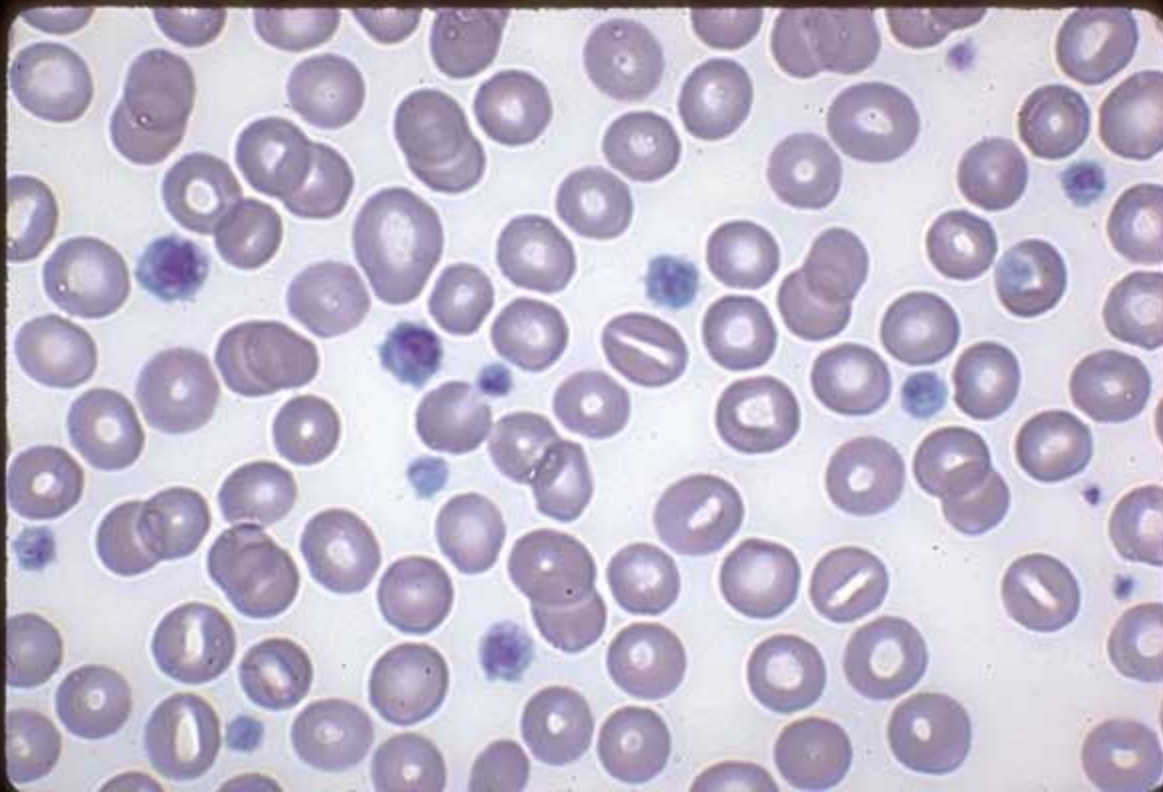Clump of Platelets, Normal Capillary blood



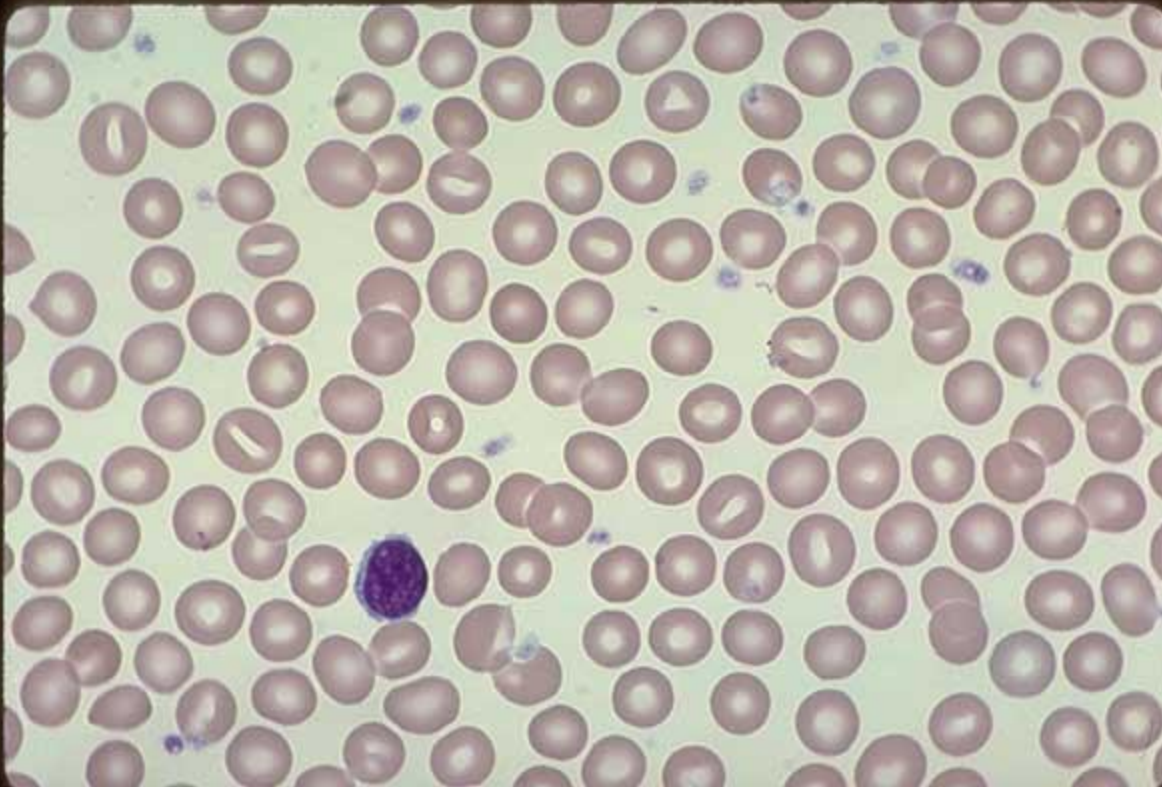Megathrombocyte, Normal capillary blood smear



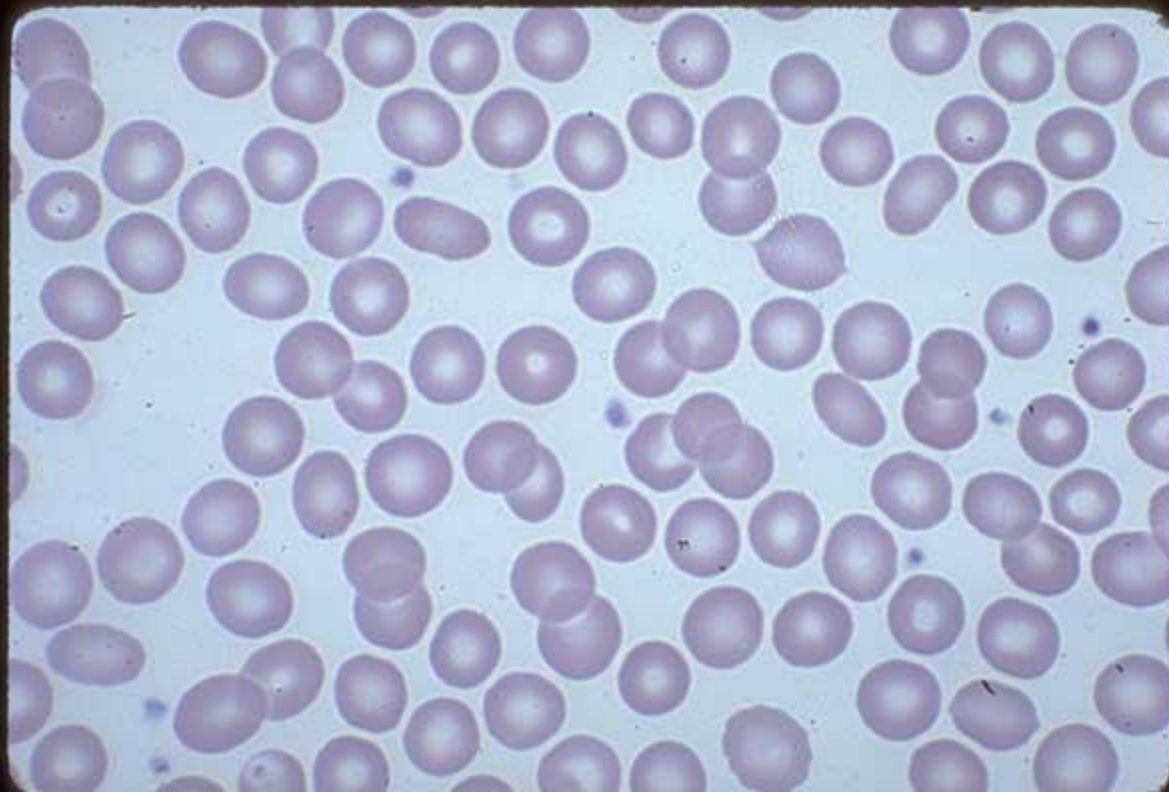
Small Platelets, Megathrombocytes



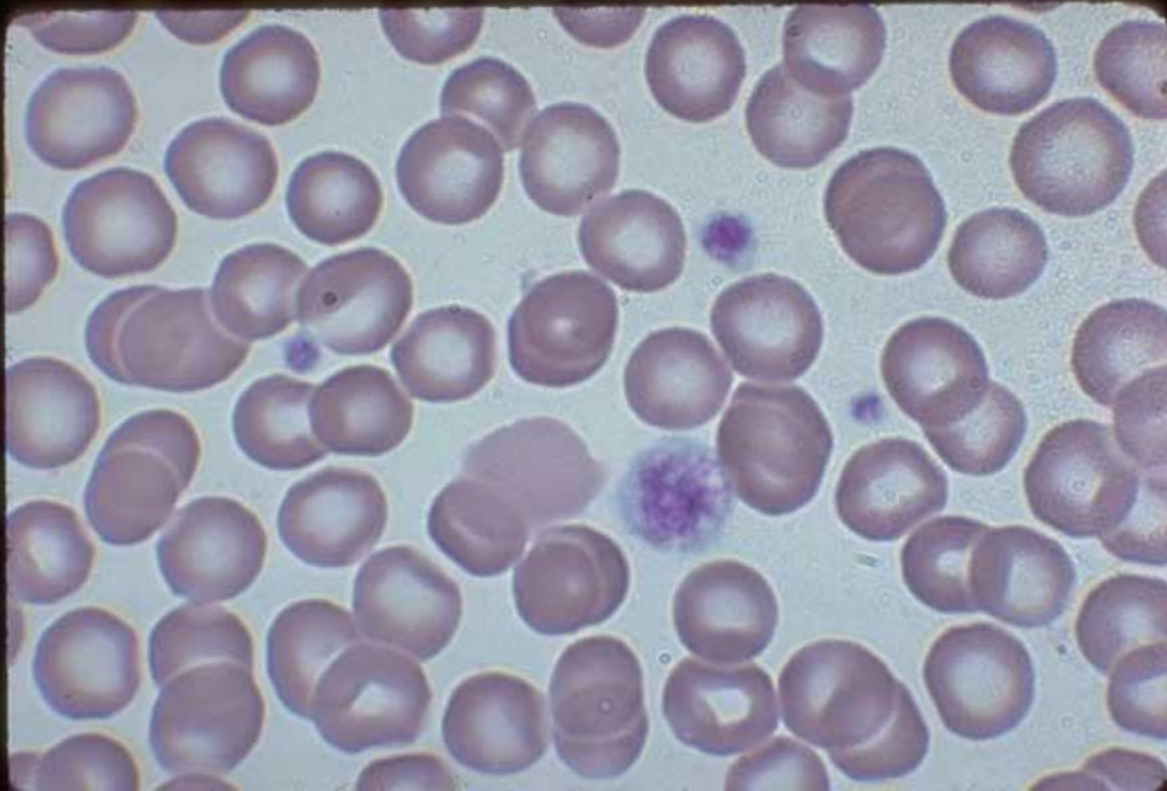Normal Platelets , Normal EDTA anticoagulated blood



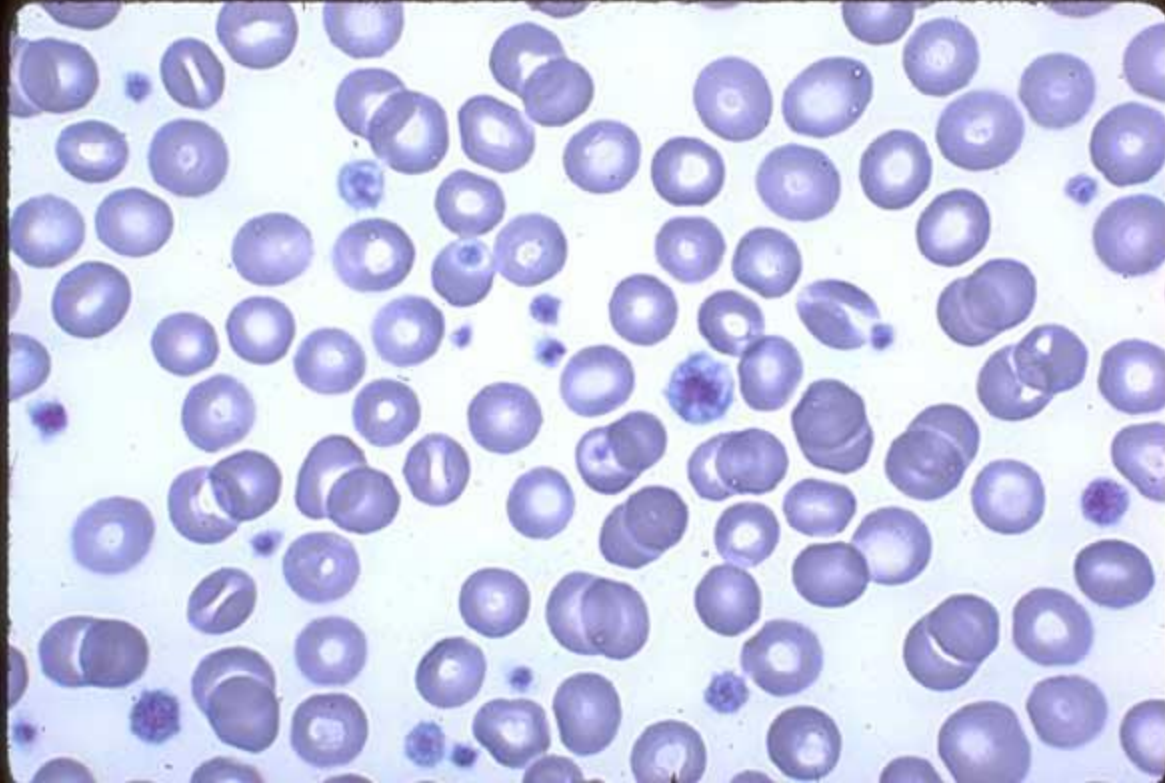
Normal Platelets, Normocytic,
normochromic RBC, Normal EDTA



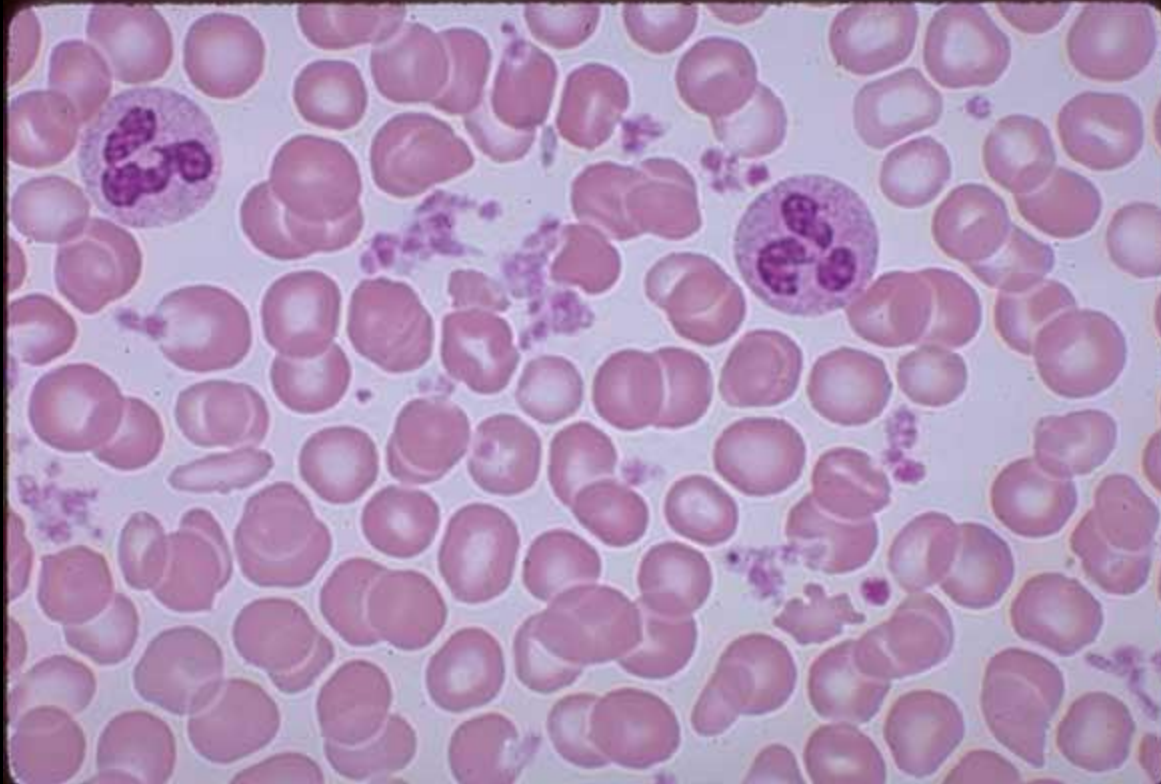
Platelets, Megathrombocyte, EDTA anticoagulated blood



Small Platelets, Megathrombocyte, Platelets Overlying RBC



Clumps of Platelets, Thrombocytosis, Capillary blood



Platelet Ribbon, Normal blood

